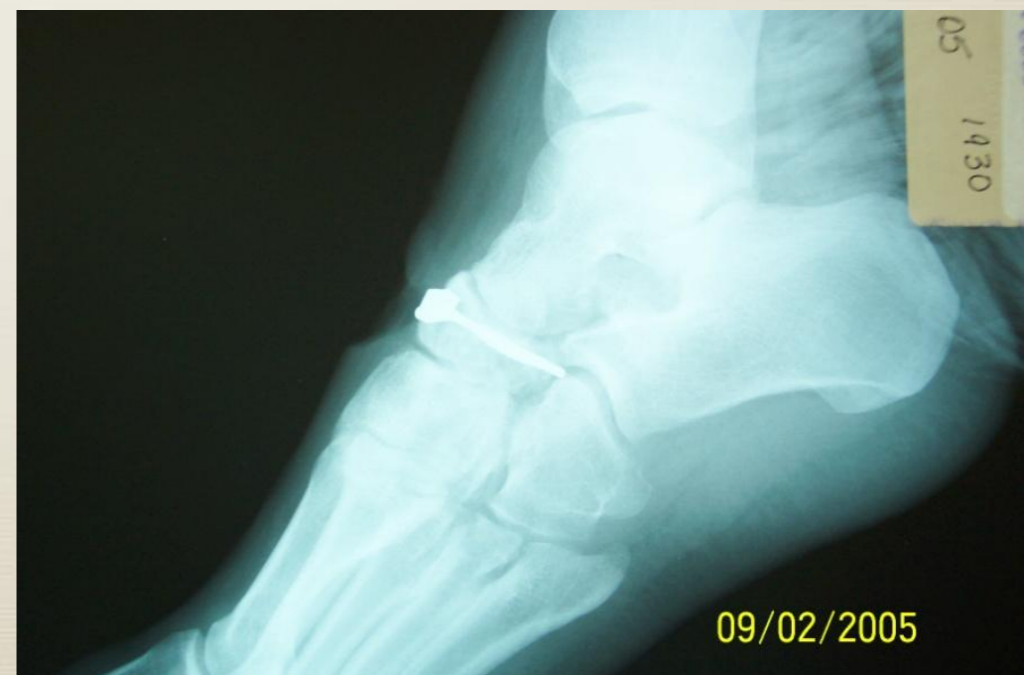
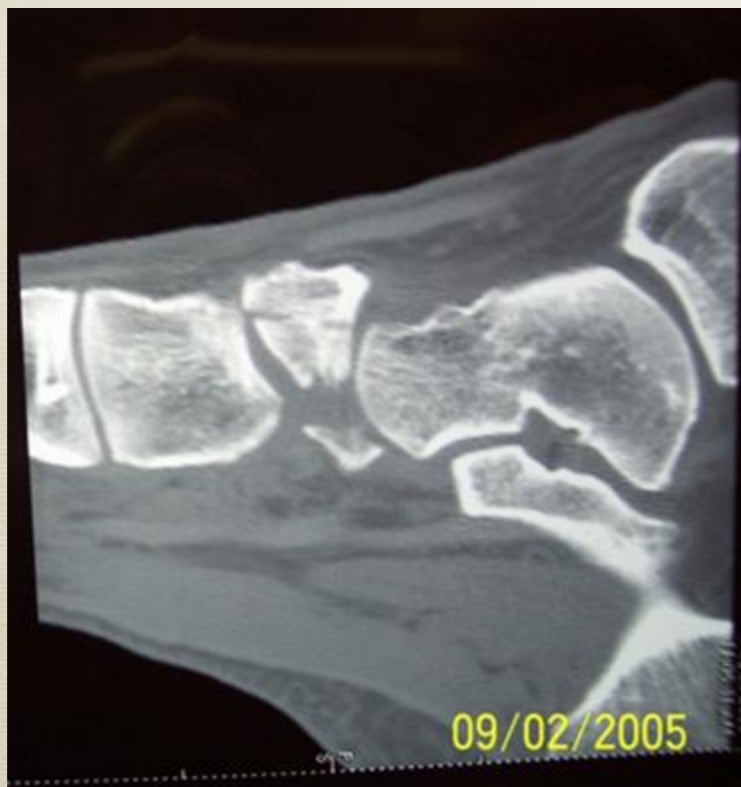
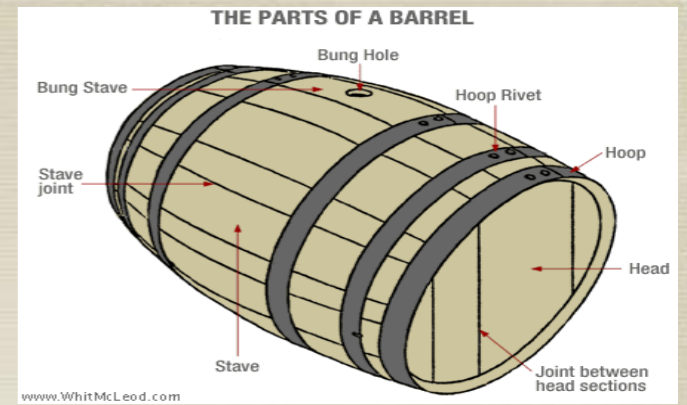
Percutaneous Navicular ORIF: A Novel Technique

I have no potential conflicts with the presentation.

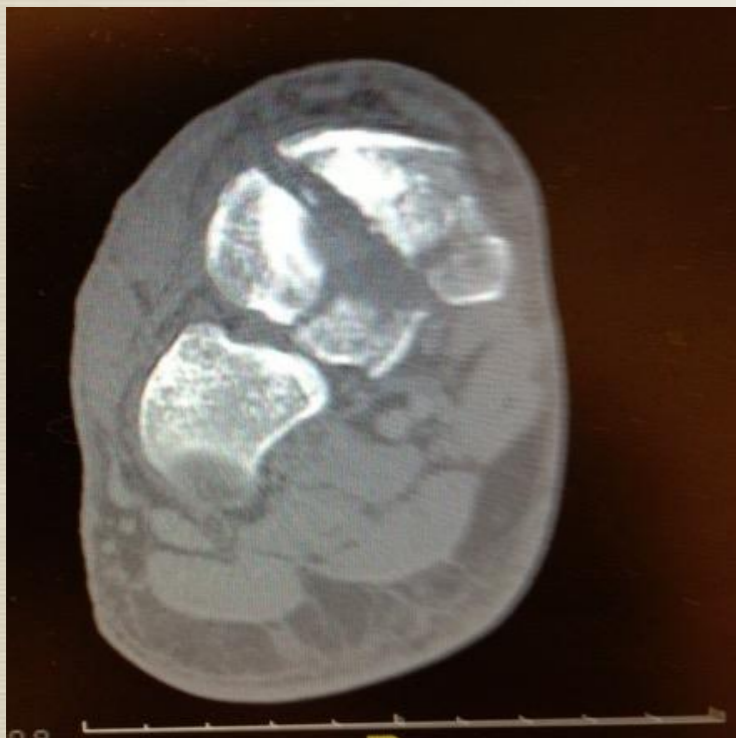Paul Kupcha MD; Geary Gutowski PA-C.



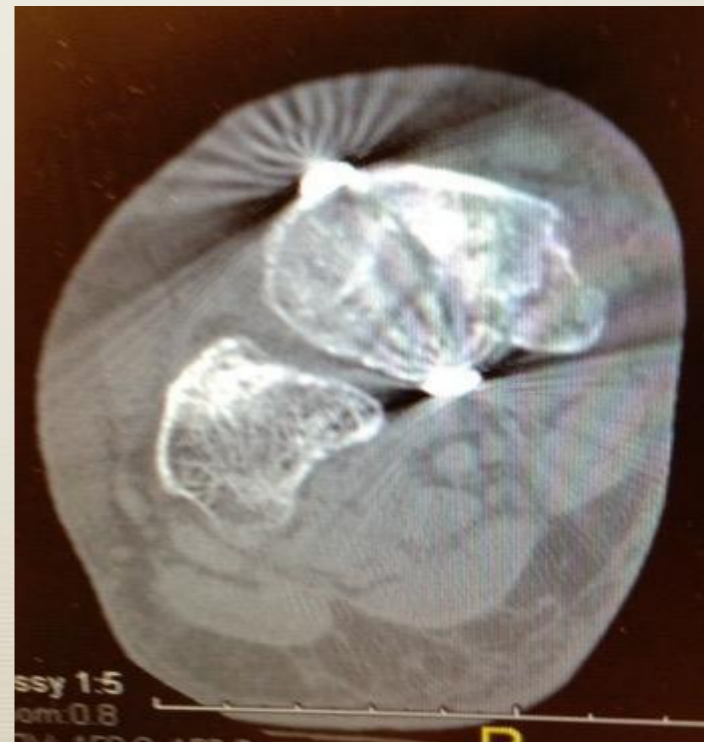Introduction



- * Navicular fractures are common midfoot fractures that are commonly missed and difficult to treat. Navicular fractures compromise 62% of all midfoot injuries.
- * Forces translating from distal to proximal cause the navicular to compress upon the talar dome. These forces cause the navicular to displace radially like staves of a barrel.
- * Cerclage cable wiring has been described to neutralize the mechanism of injury.

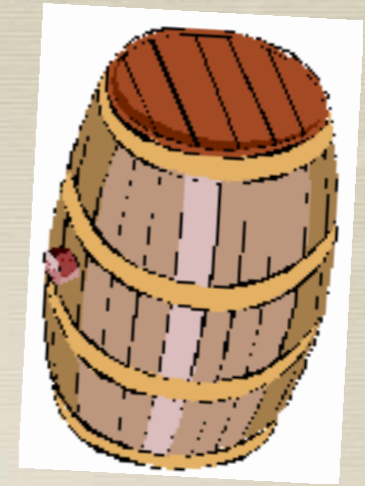


Note: Radial displacement of fracture fragments.

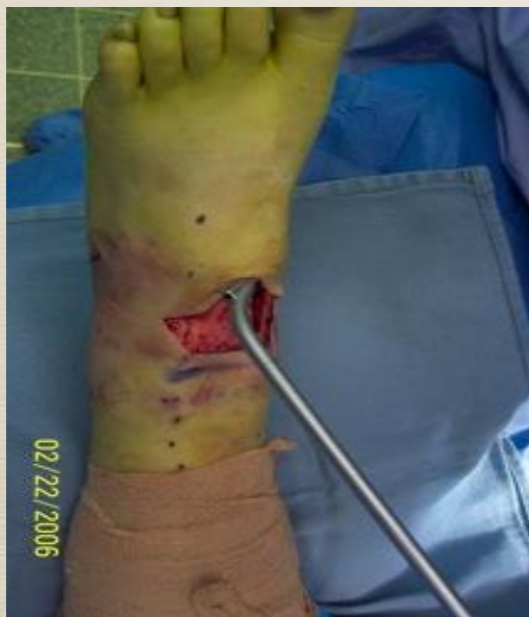

Note: Post-operative image of the fractures.

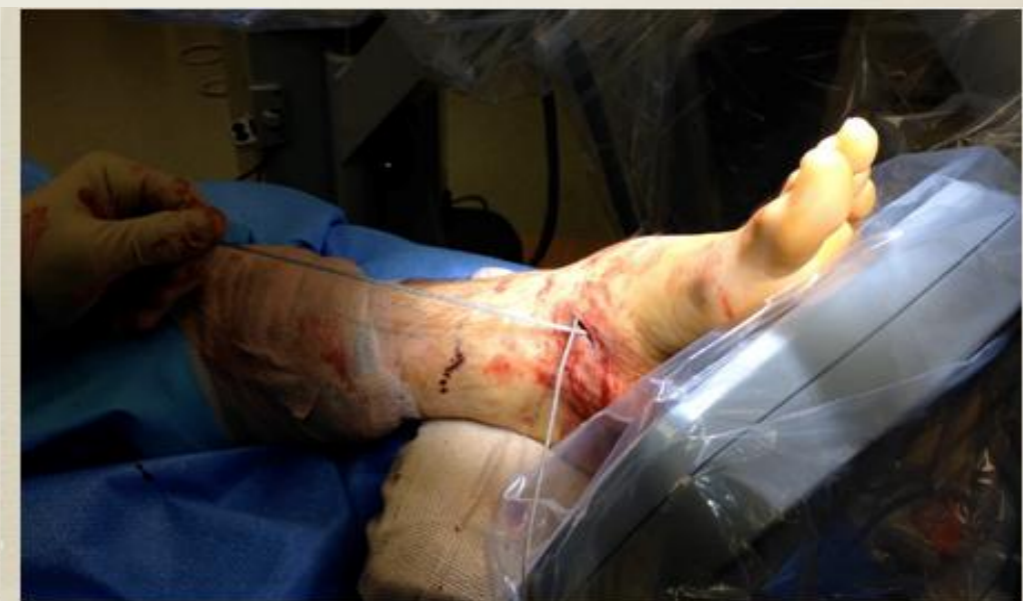Methods



- * We employed a technique for a circumferential cabling to act like a barrel hoop to reverse and neutralize the deforming radial forces. A 2005 case report in Foot and Ankle International described a single case fixed with an open wiring technique.
- * Initially a transverse open technique with a large wire passer was utilized. This was abandoned in favor of a percutaneous method using two -1 cm incisions.
- * A single surgeon performed all 20 surgical cases of cabling.



Open Technique

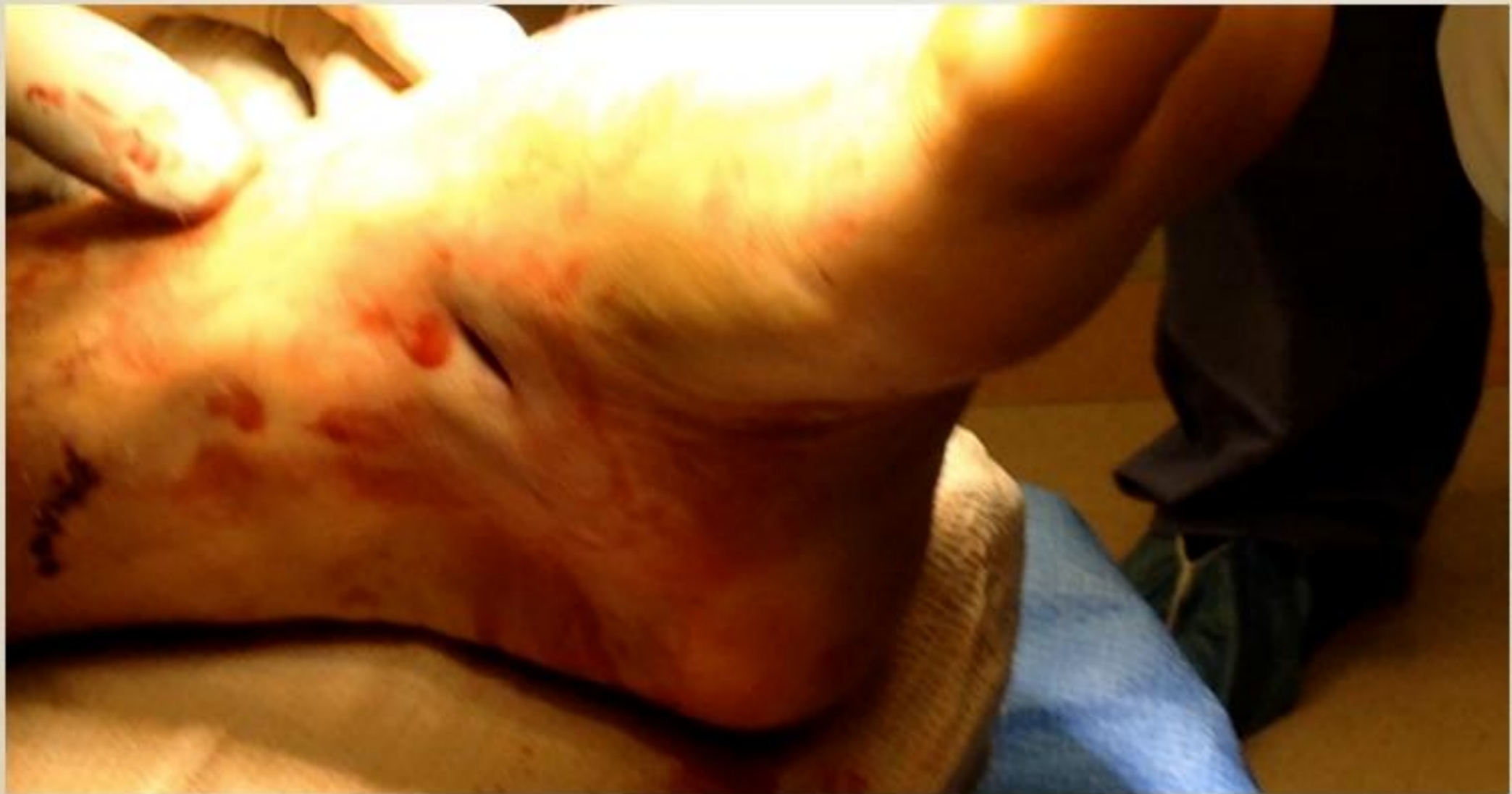

Percutaneous Technique

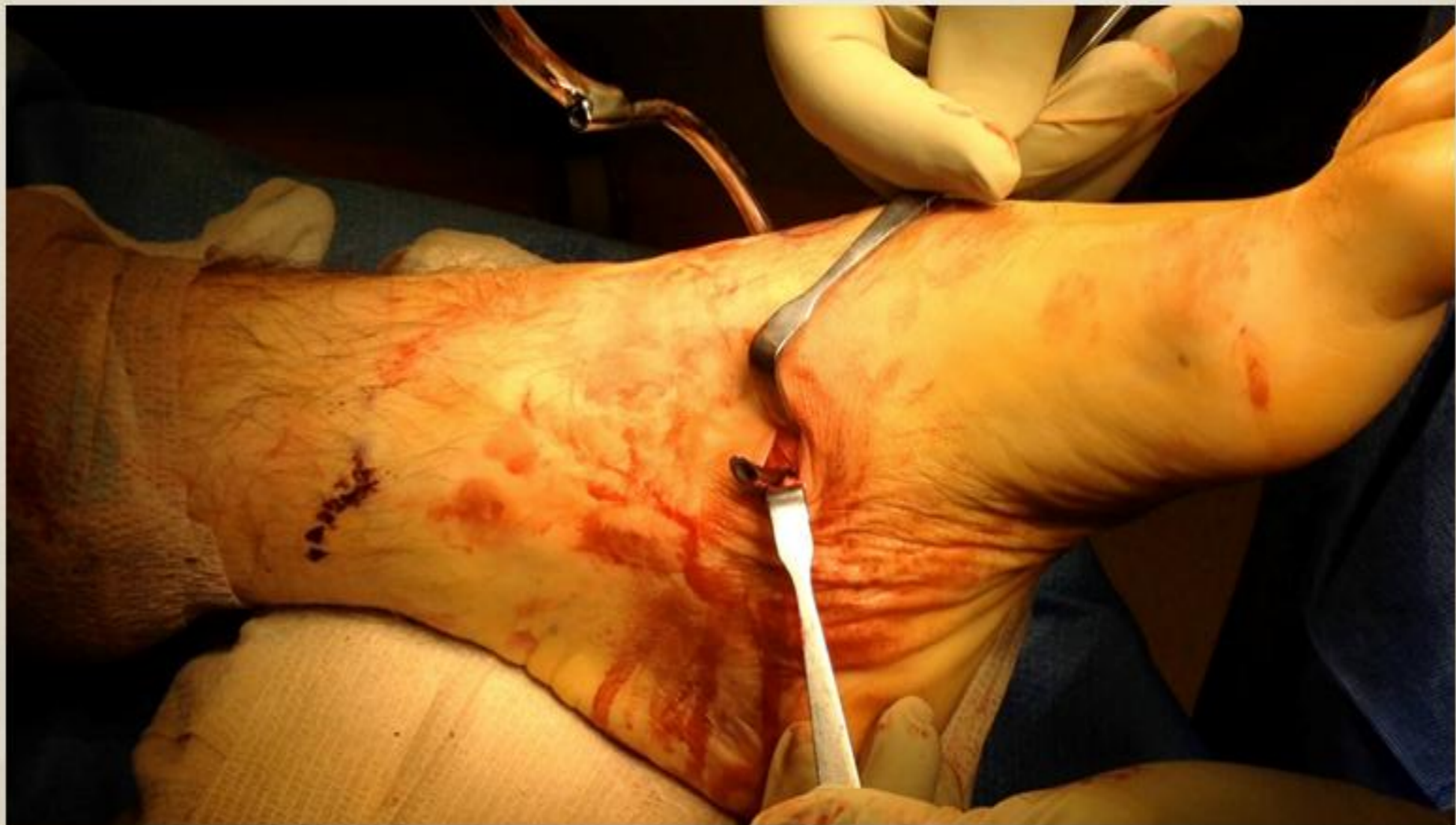Surgical Technique

- * **The approach evolved from an open transverse dorsal incision to a percutaneous technique. Two small incisions were made over medial and lateral poles of the navicular to pass the cable. The cable was either passed with the trochanteric cable passer or was pulled into place after first passing a more malleable high tension suture. Fluoroscopy was used intra-operatively.**

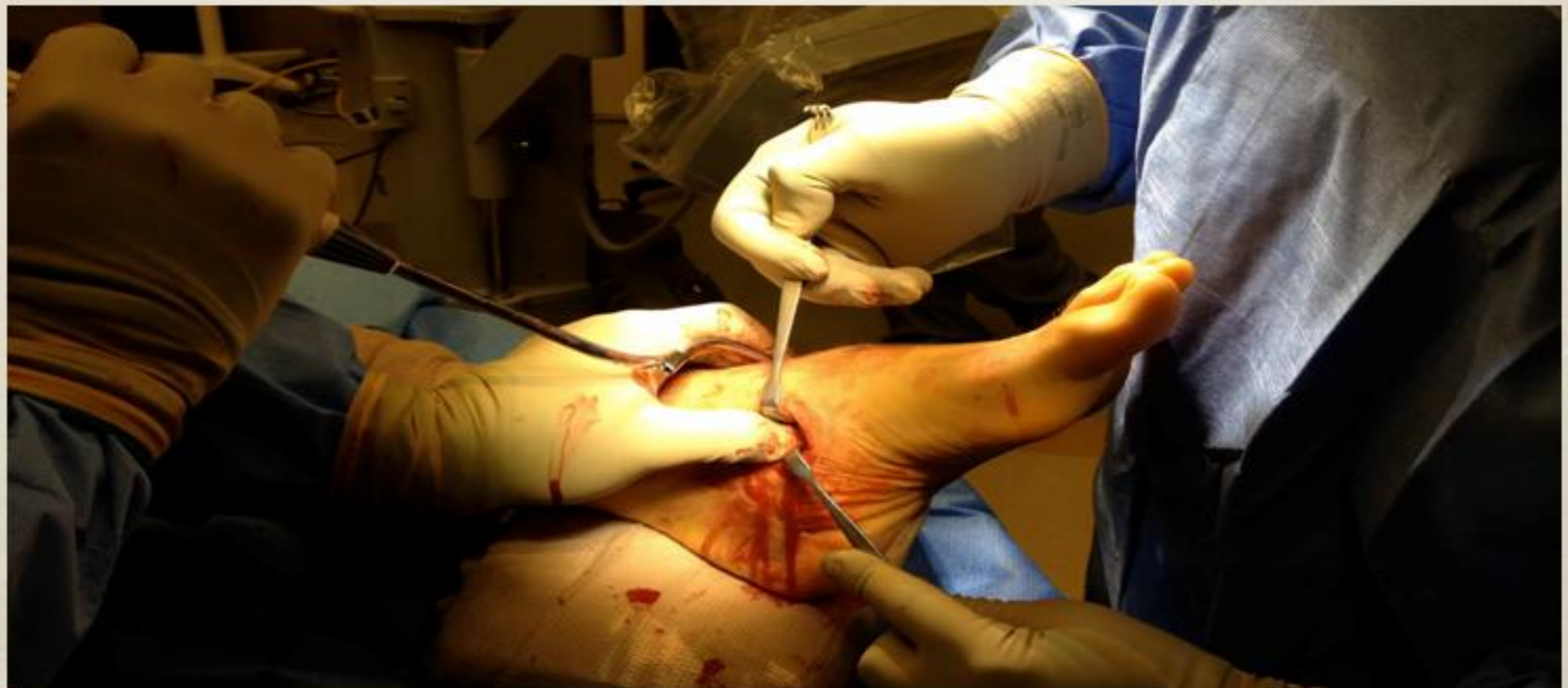A small incision made over medial pole of the navicular.



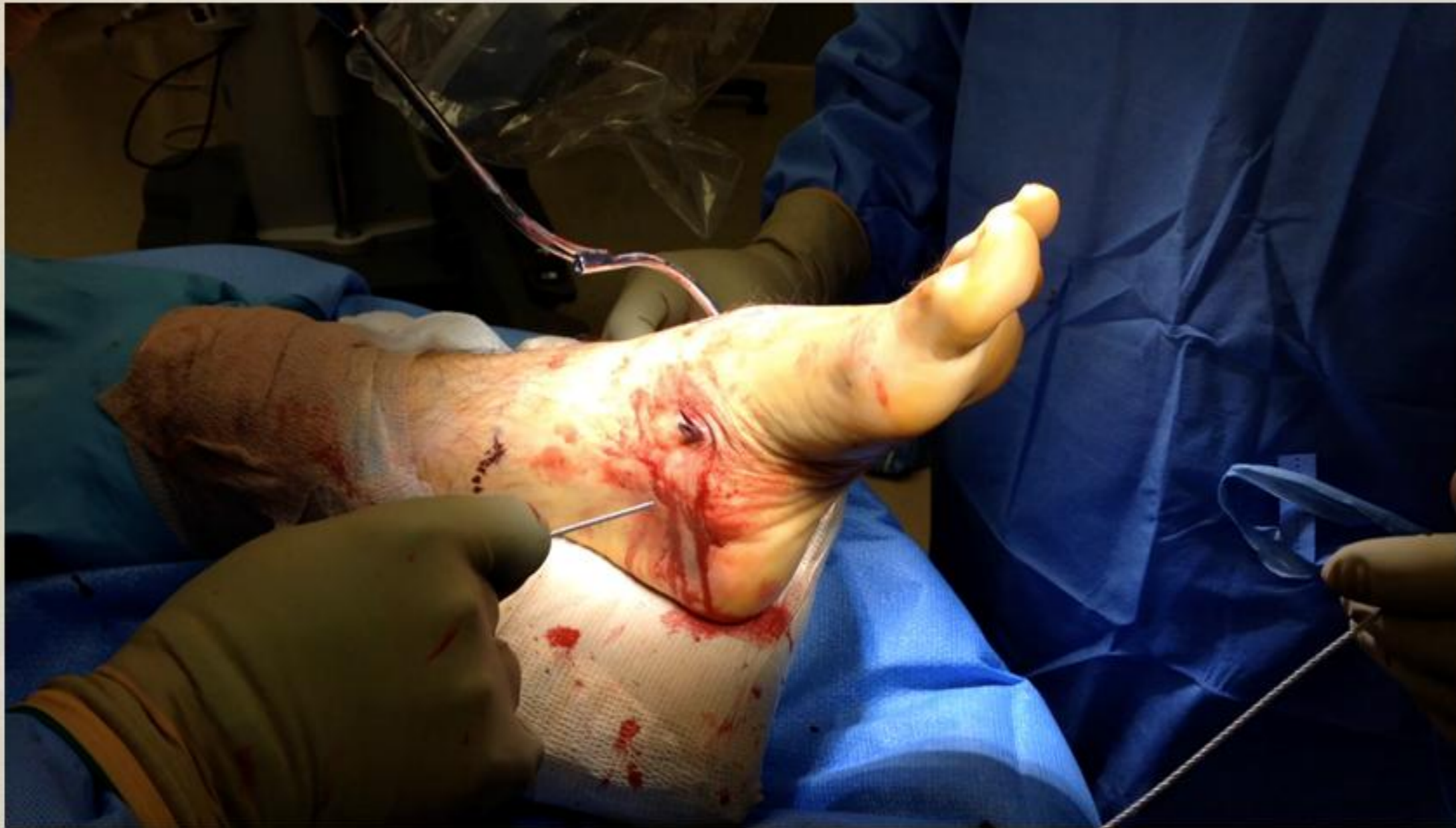The Dahl-Miles cable passer is passed from either pole plantar along the navicular.



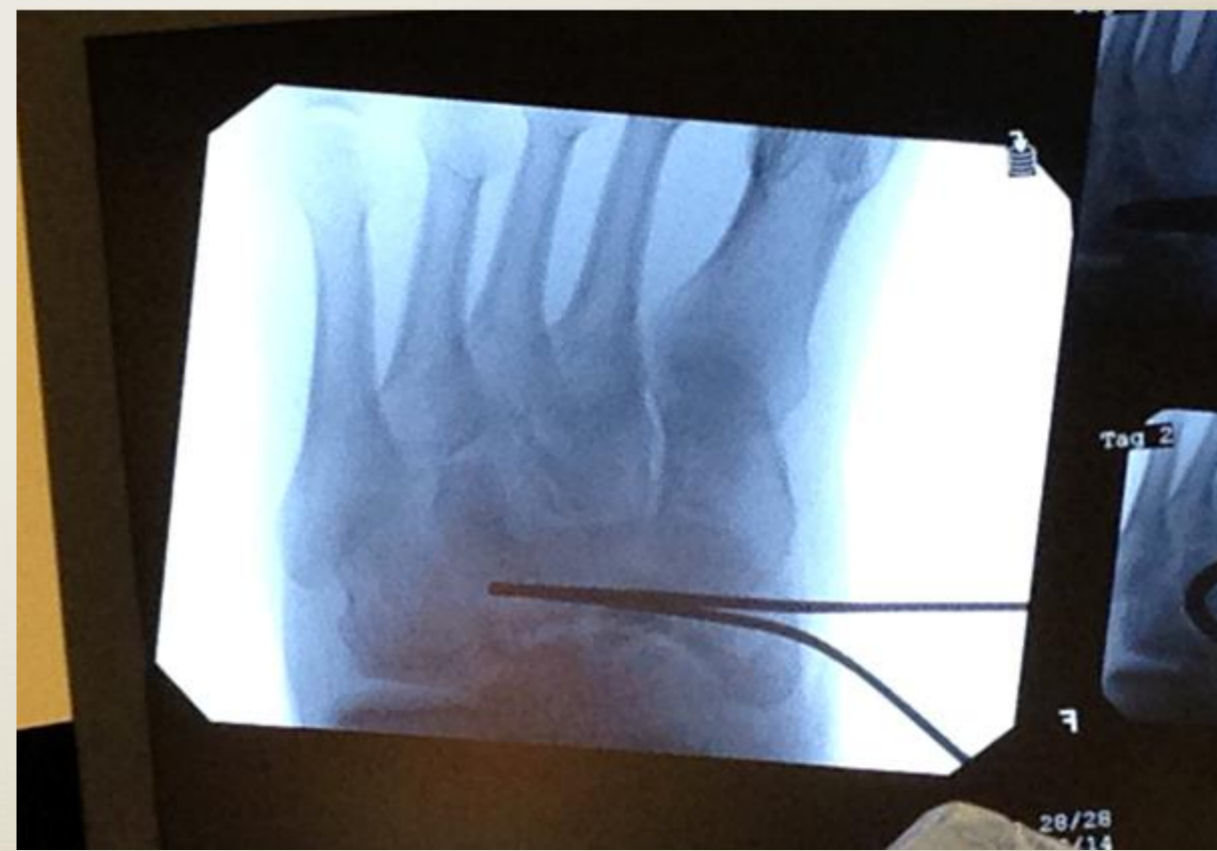
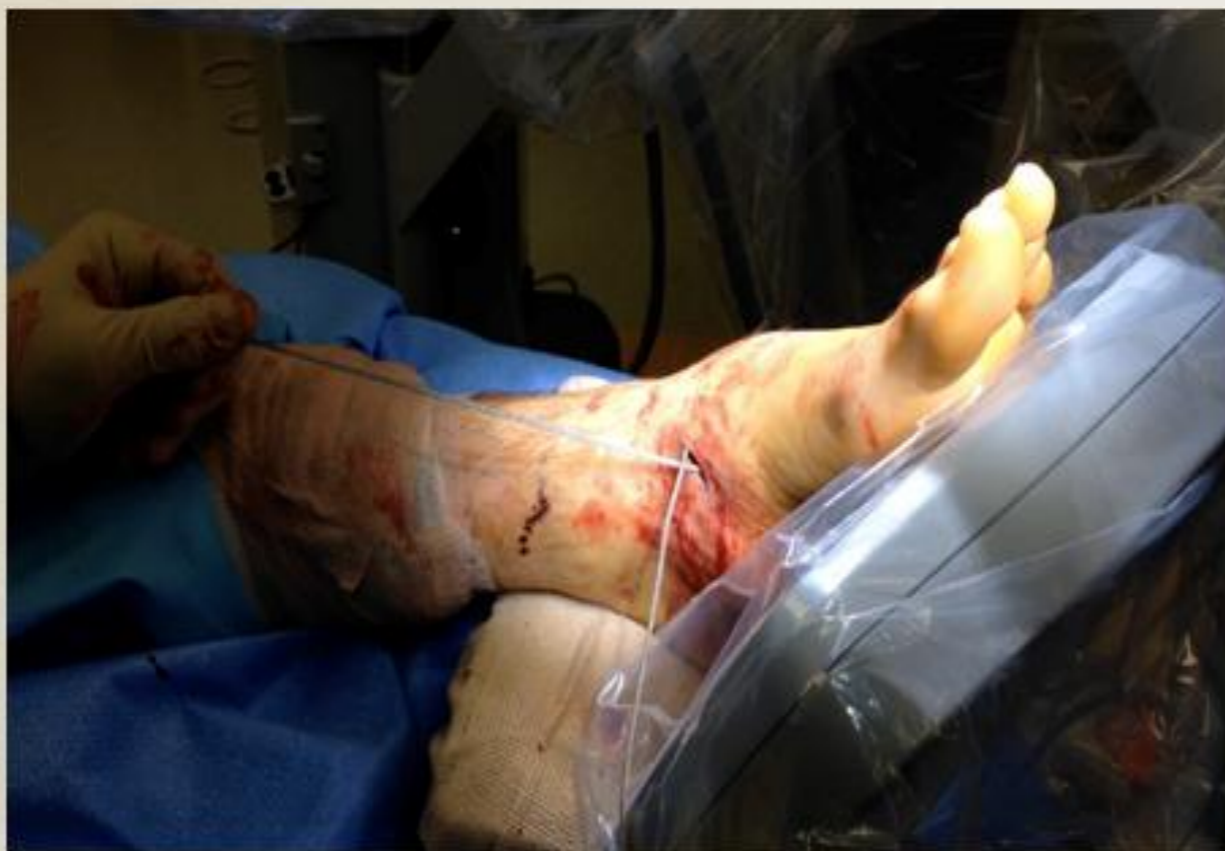Flourosocopy can be utilized for incision positioning. The Dahl-Miles cable passer is passed from either pole plantar along the navicular. *Note: passer being inserted from lateral to medial pole.*



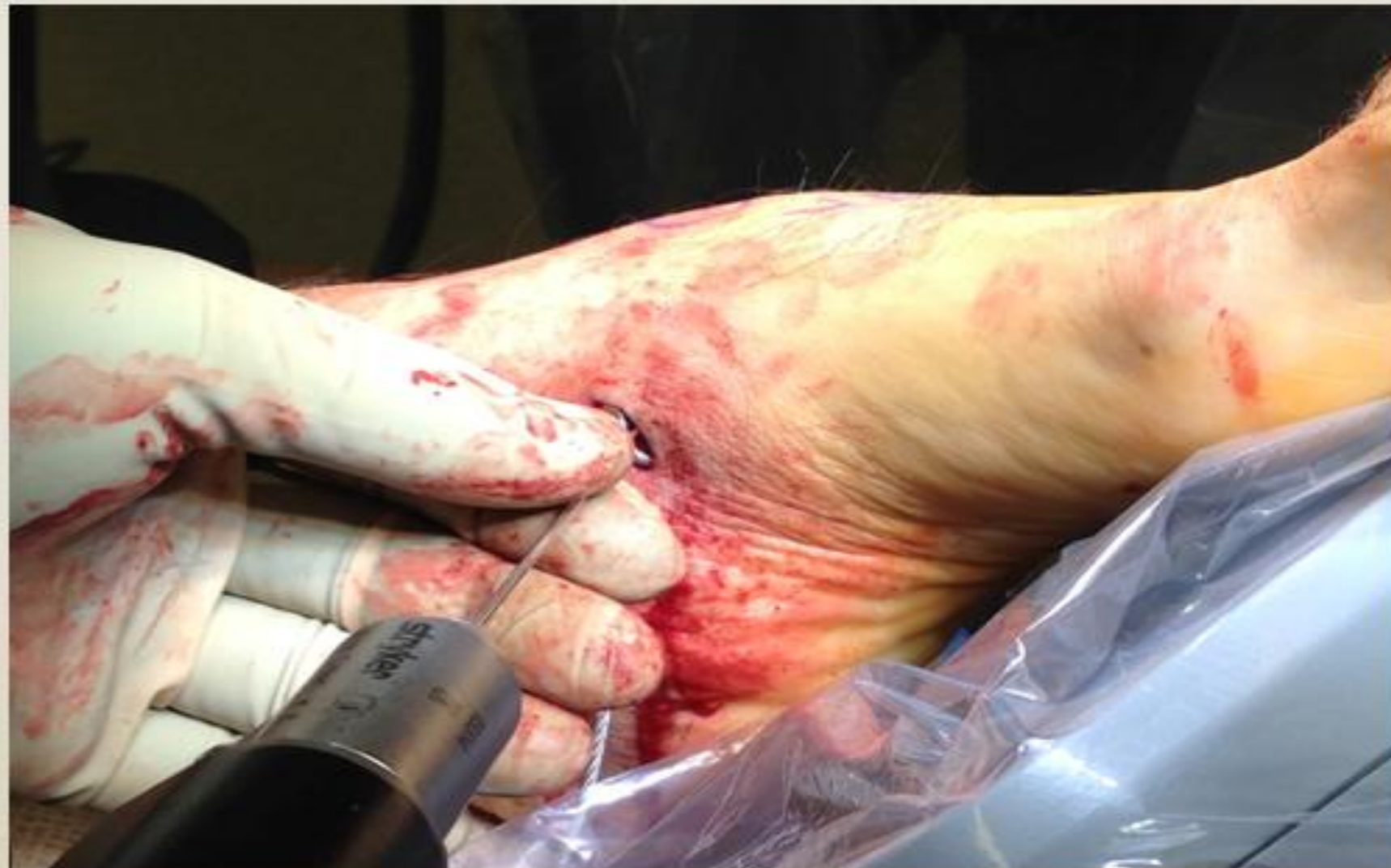Pass tip of cable through the cannulation of the cable passer.



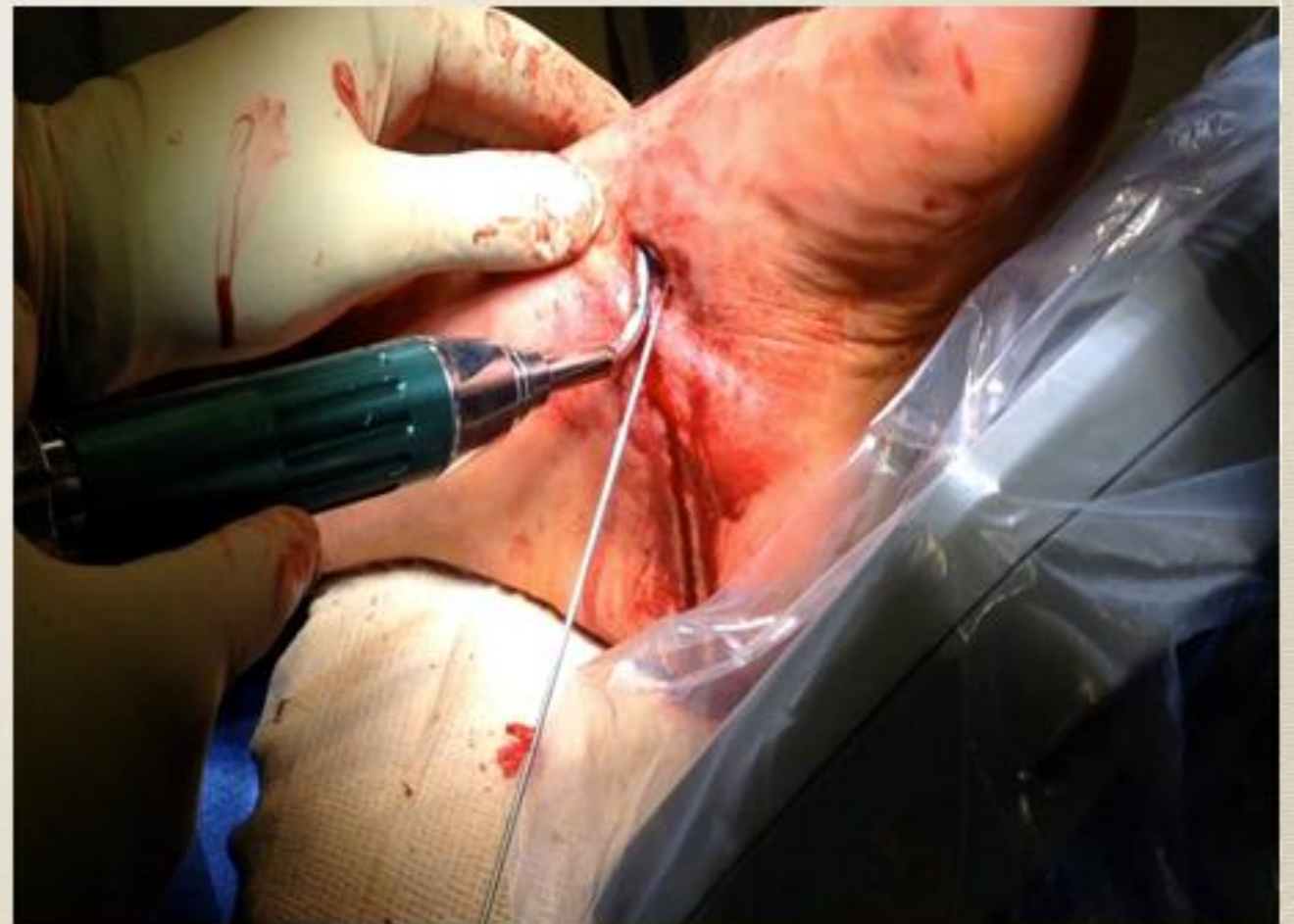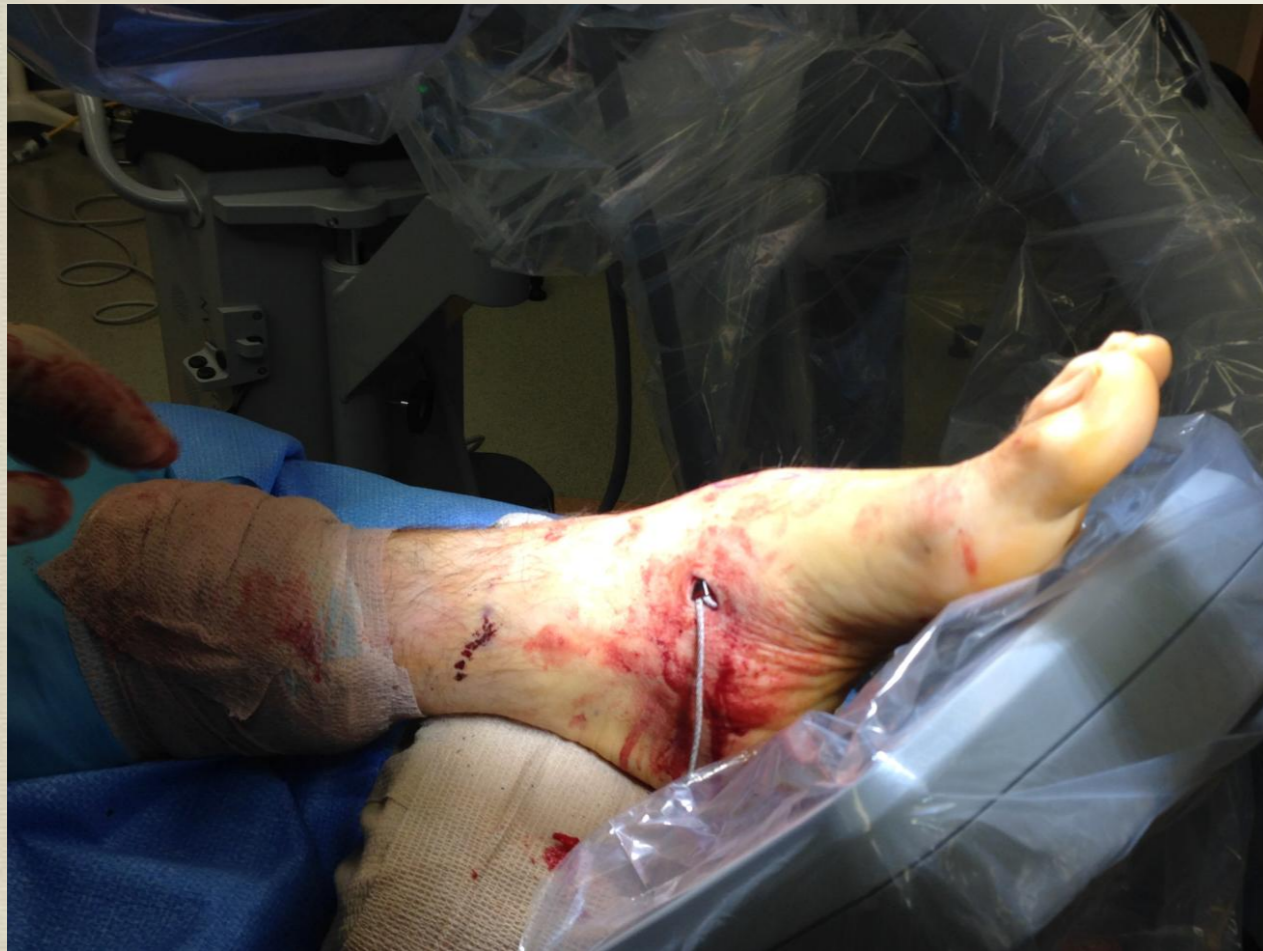**The cable is then passed dorsally
with a kelly or curved hemostat into
the same incision**



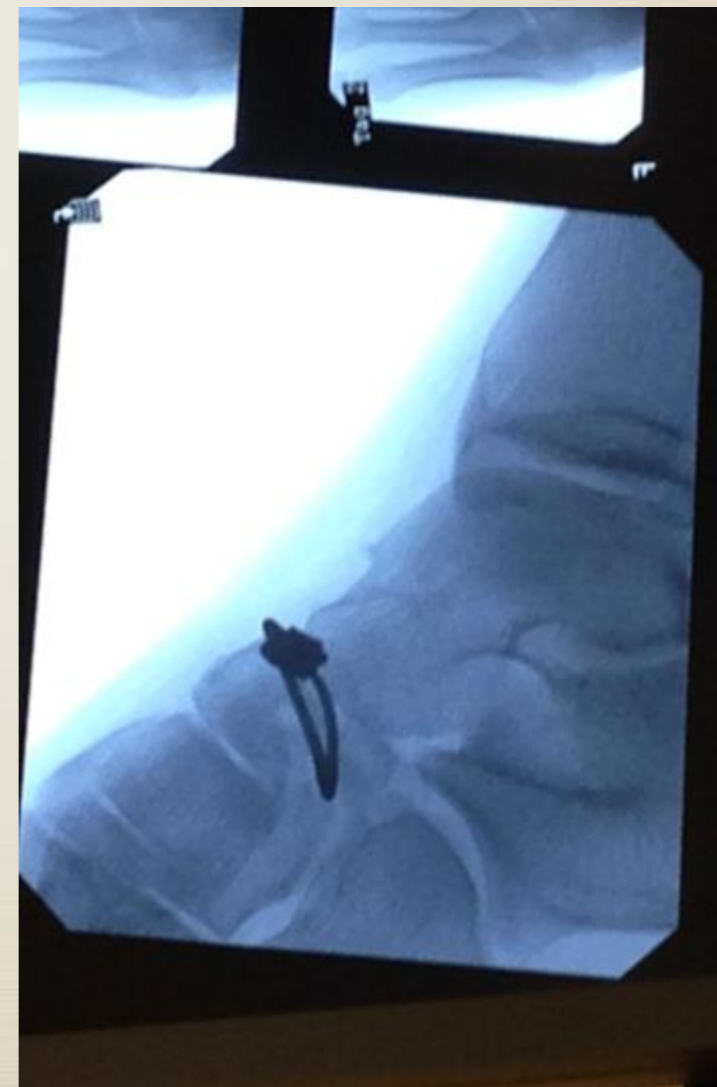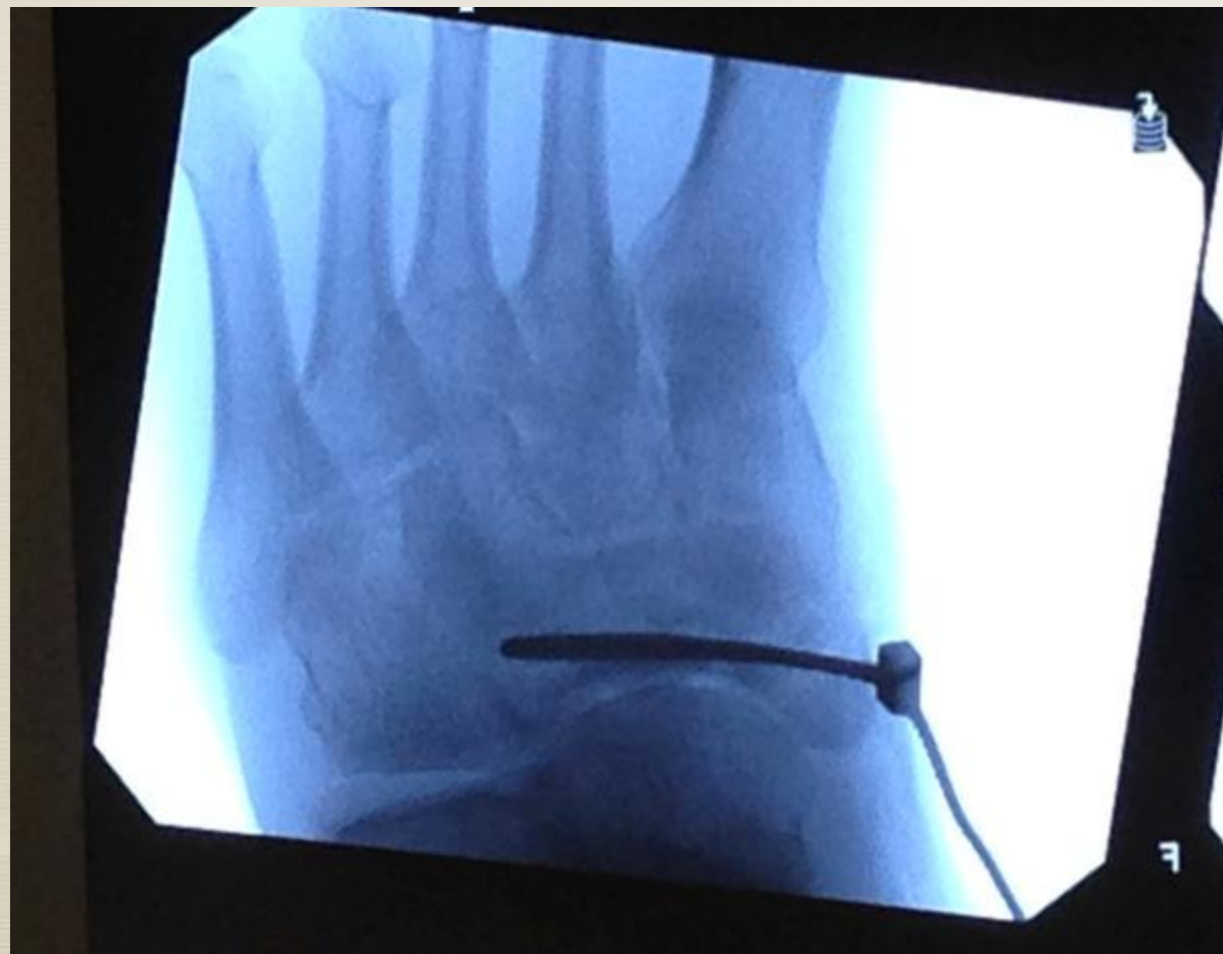Blocking (positional) K-wires can be placed to fine tune position of the cable prior to tensioning if needed.



Crimping block is placed and the wire tensioned. After which the cable is cut.

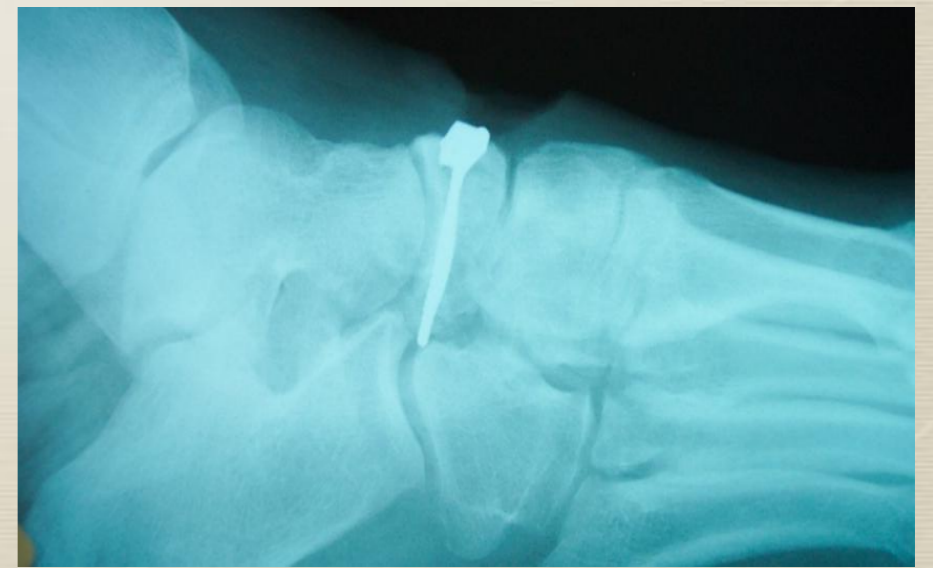
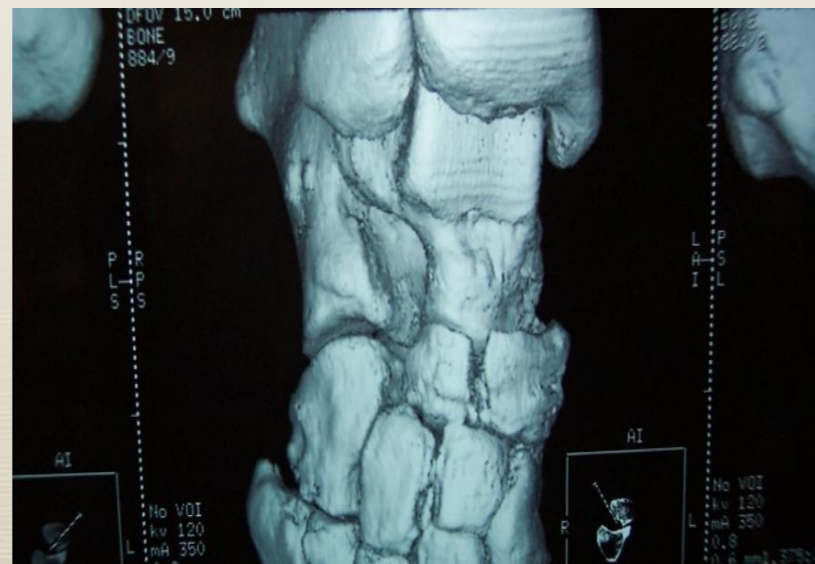
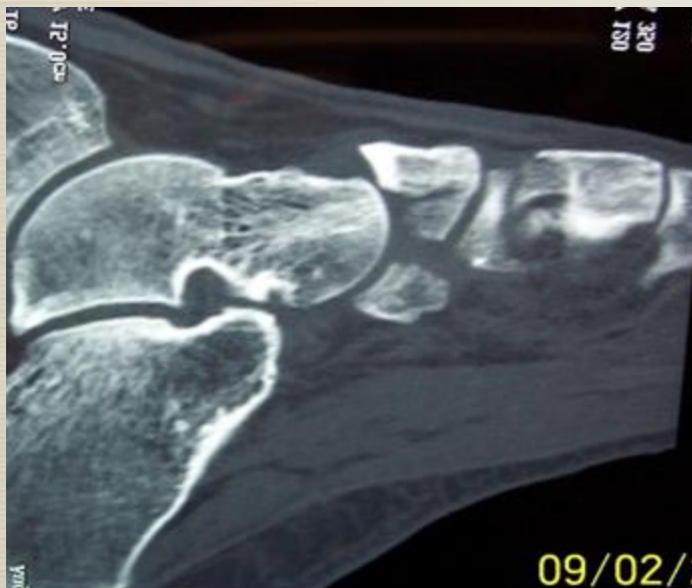Intra-operative images before cutting the cable.



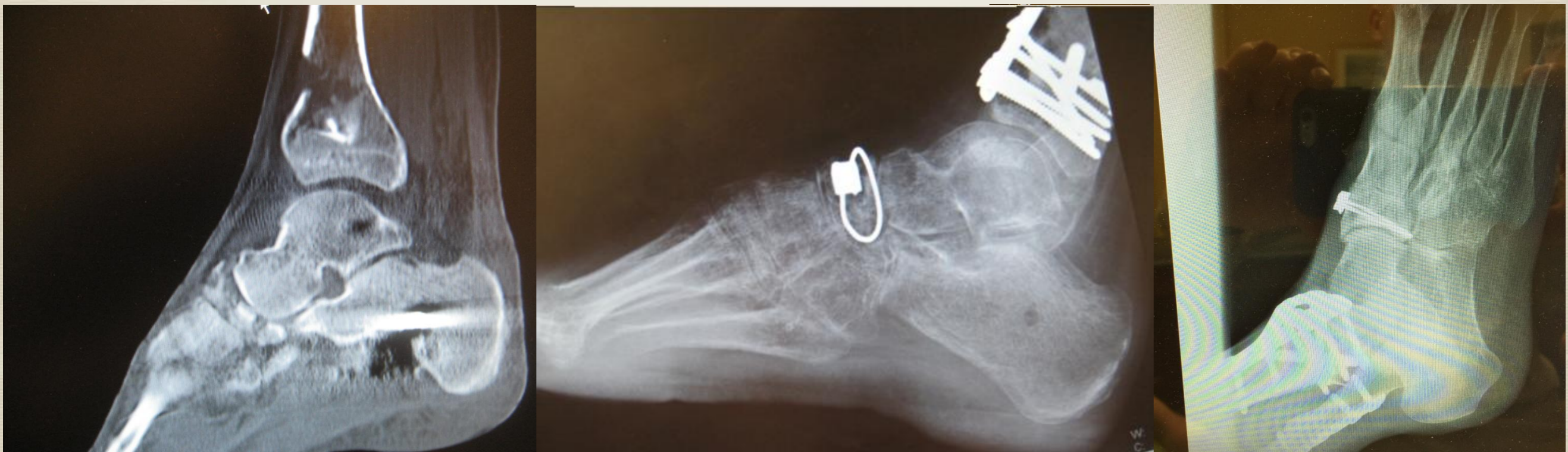Results

- * **We believe that this technique results in superior fixation of navicular fractures.**
- * **Circumferential cabling neutralizes the deforming forces by reversing the mechanism of injury**
- * **These cases demonstrate a safe, quick, minimal incision surgical technique which provides excellent fixation of the navicular fracture fragments.**

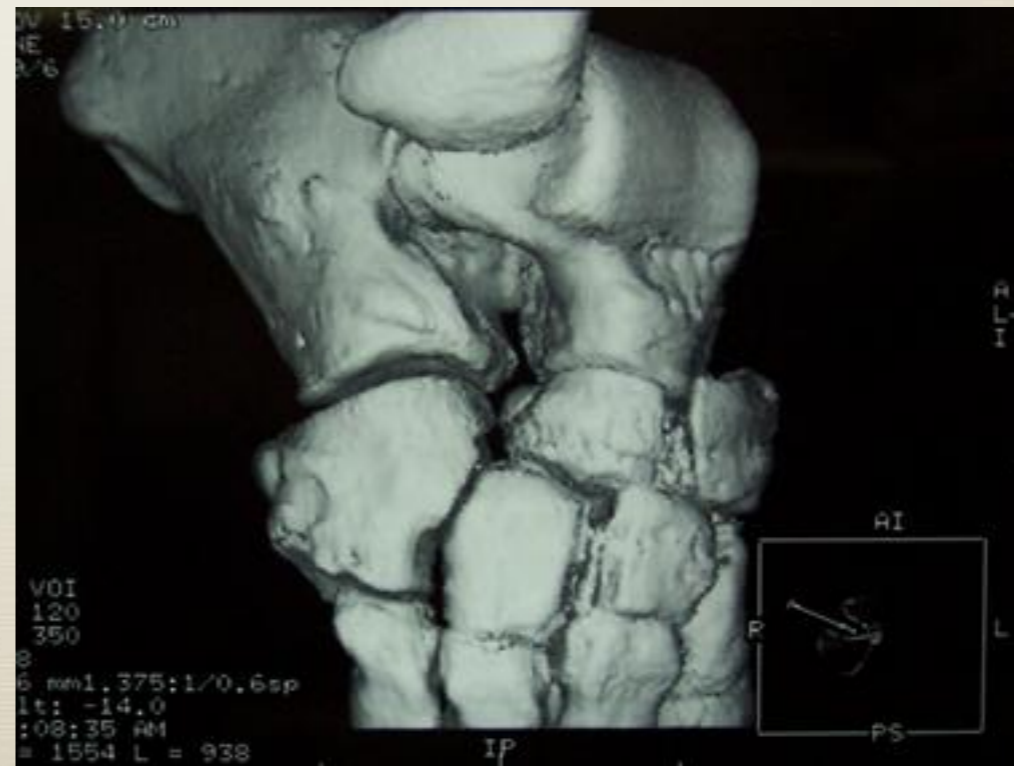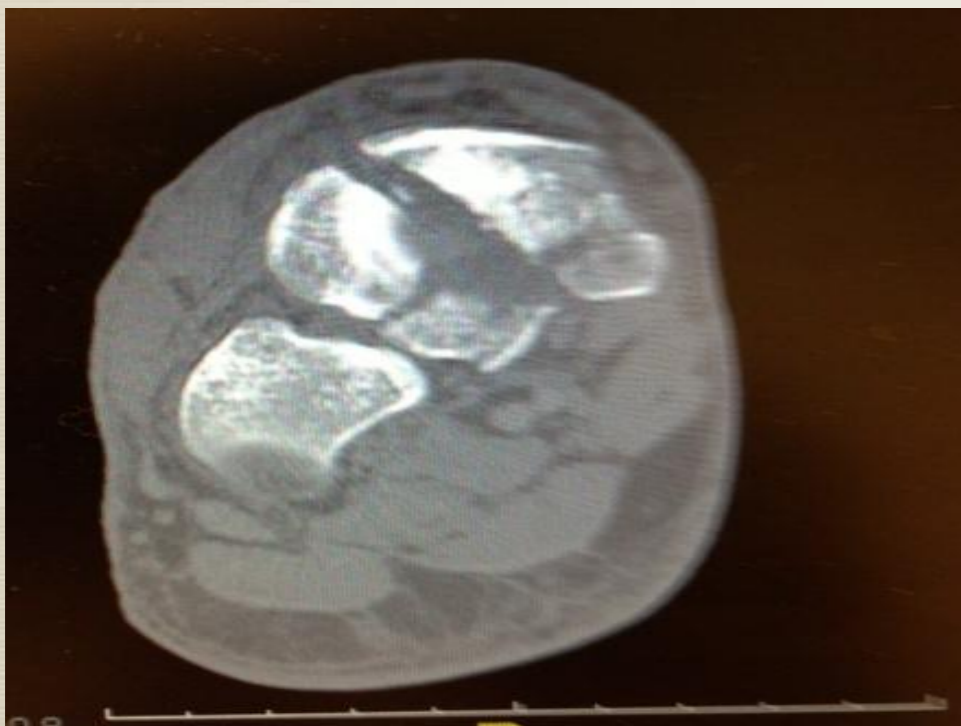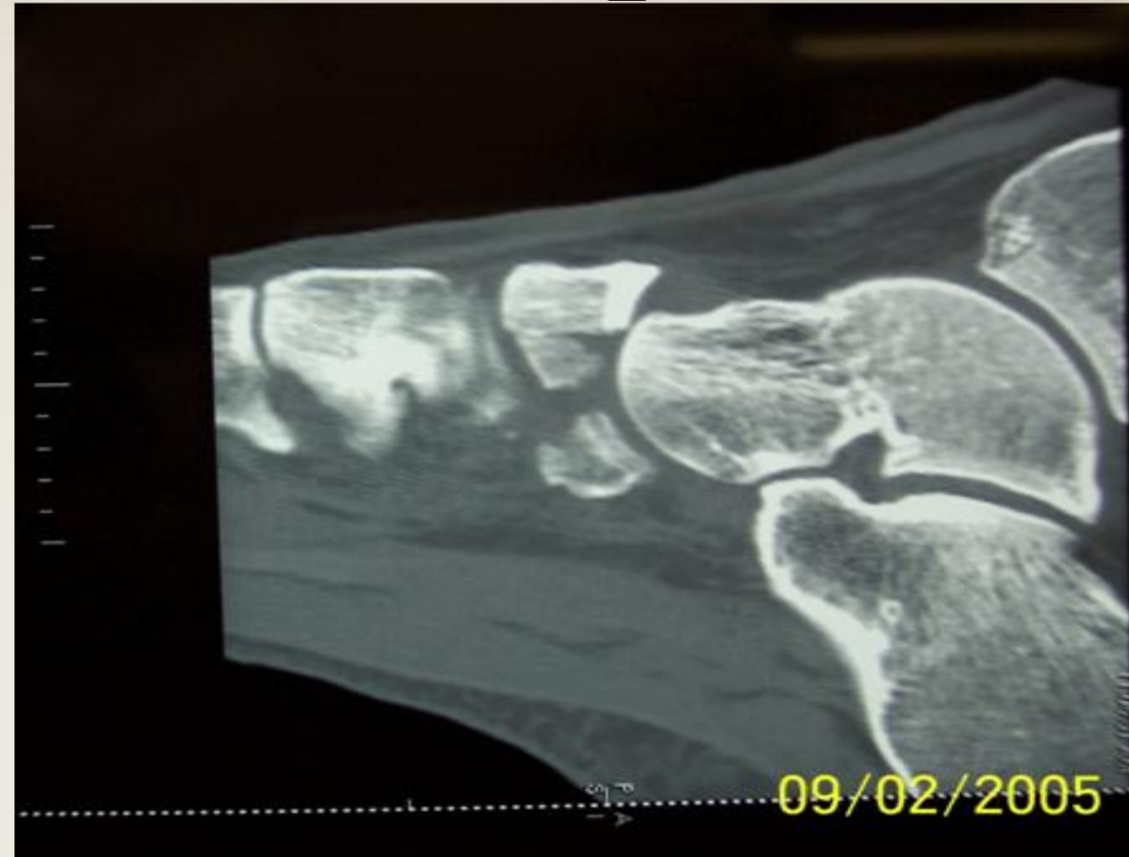


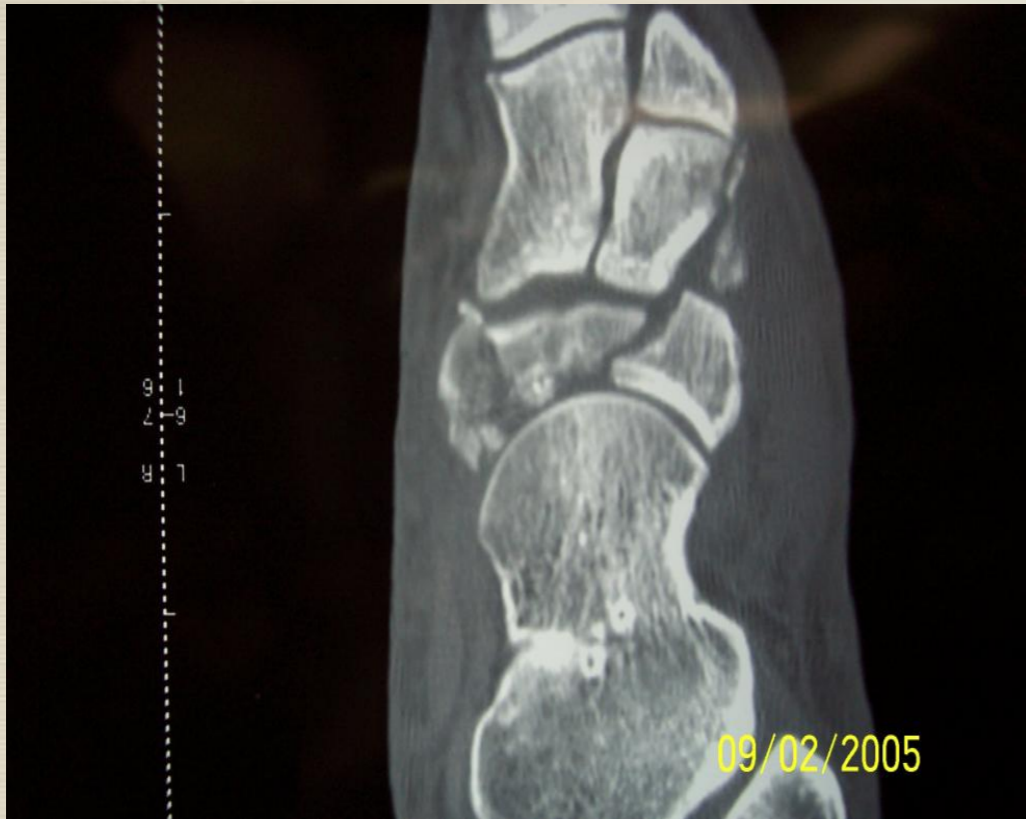Conclusion

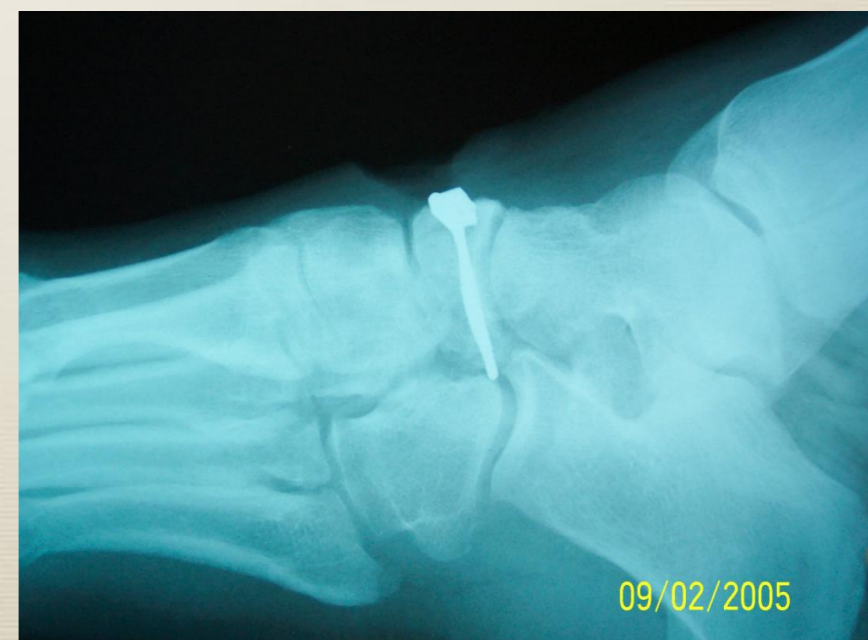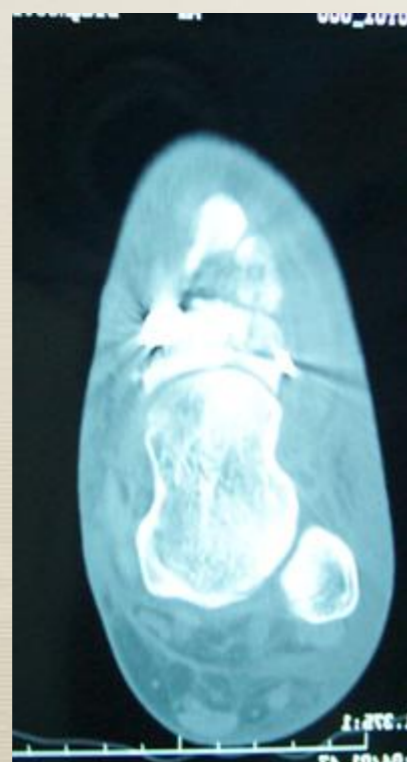
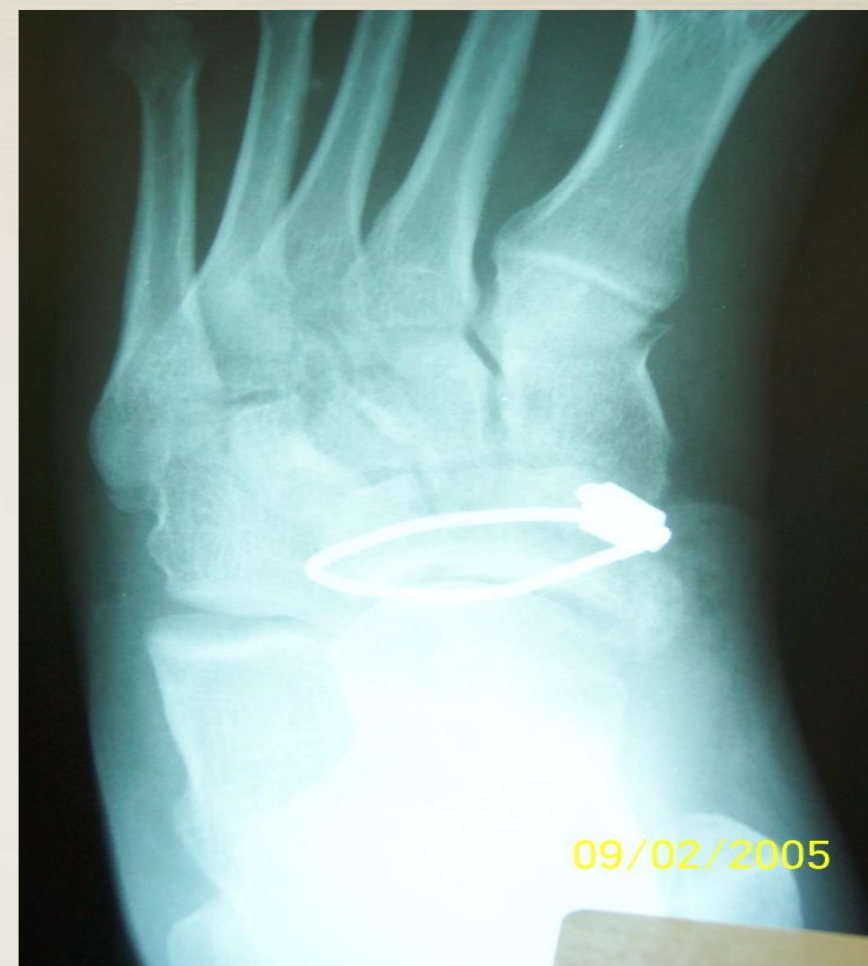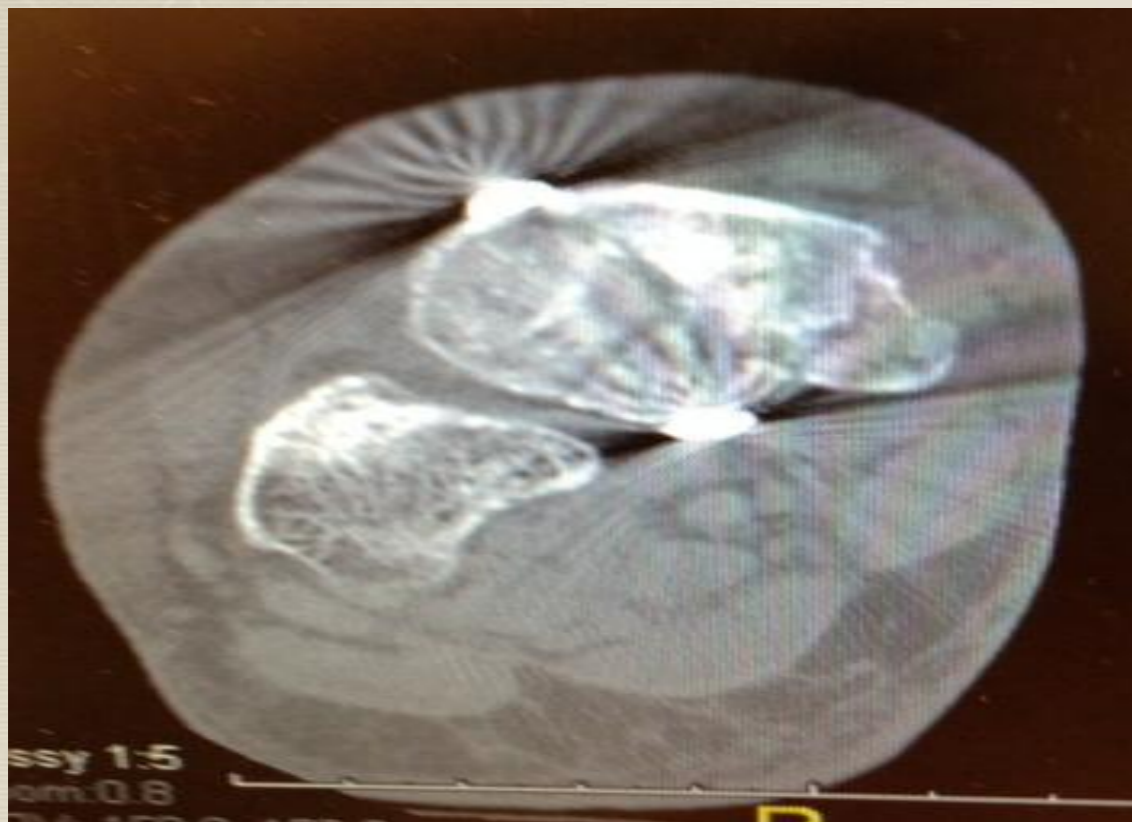- * **Percutaneous cerclage cabling of navicular fractures is an innovative technique to fixate these fractures.**
- * **This surgical technique is safe and expedient.**
- * **We believe that this series patients conclusively shows excellent reduction and fixation.**



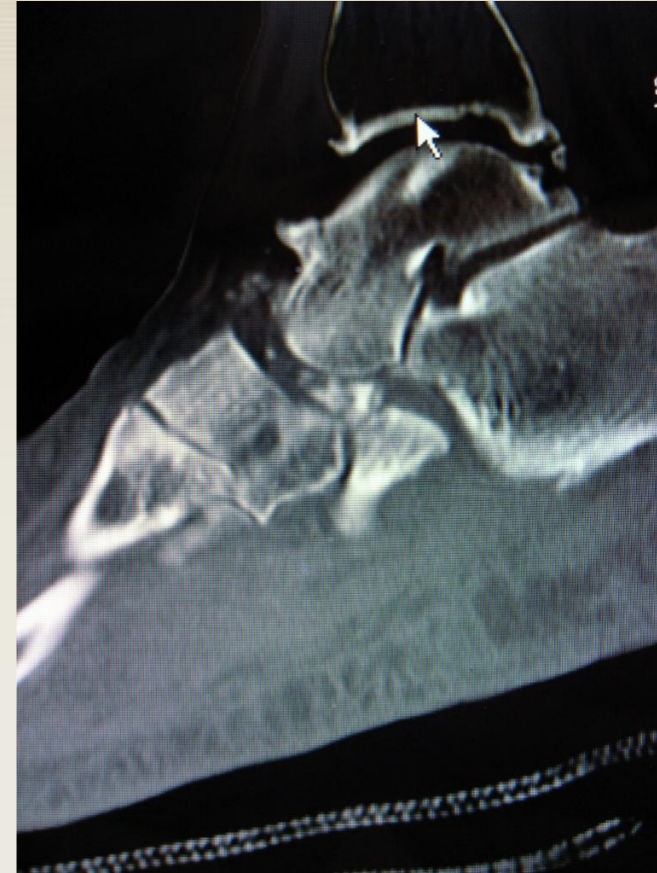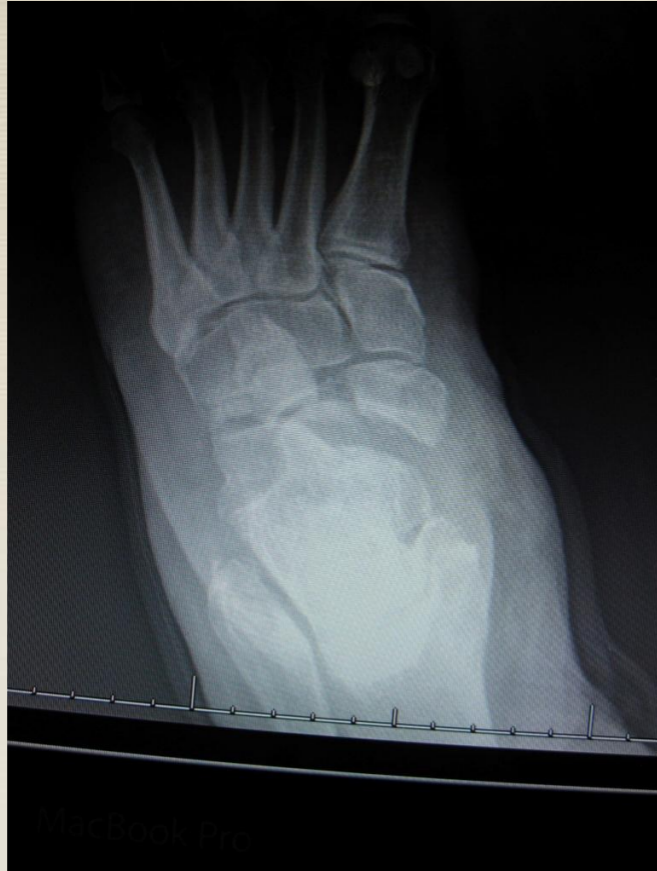Additional Illustrative Pre-operative Case Images



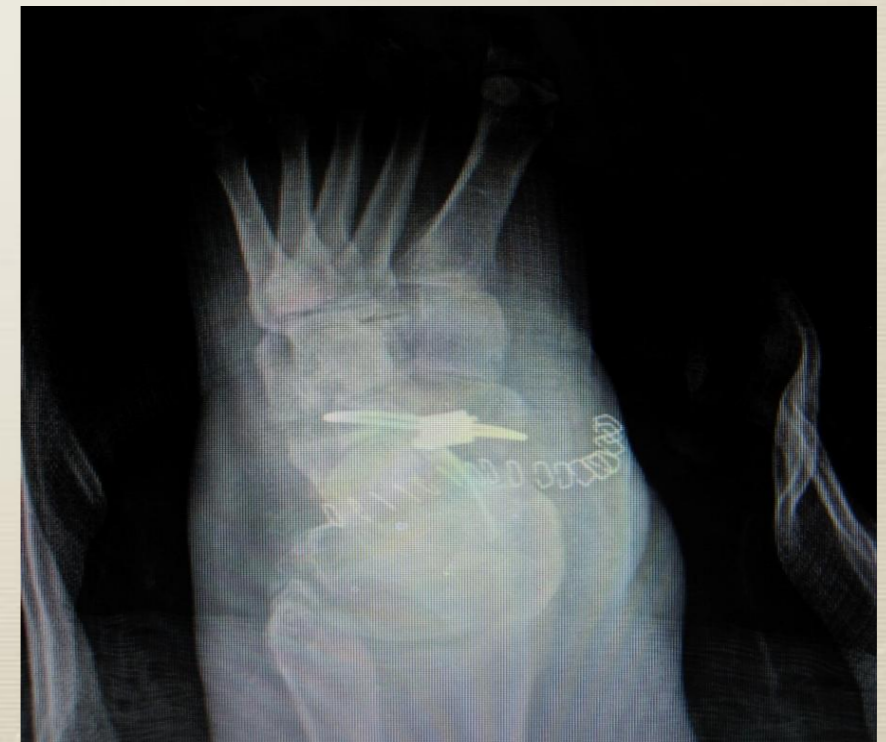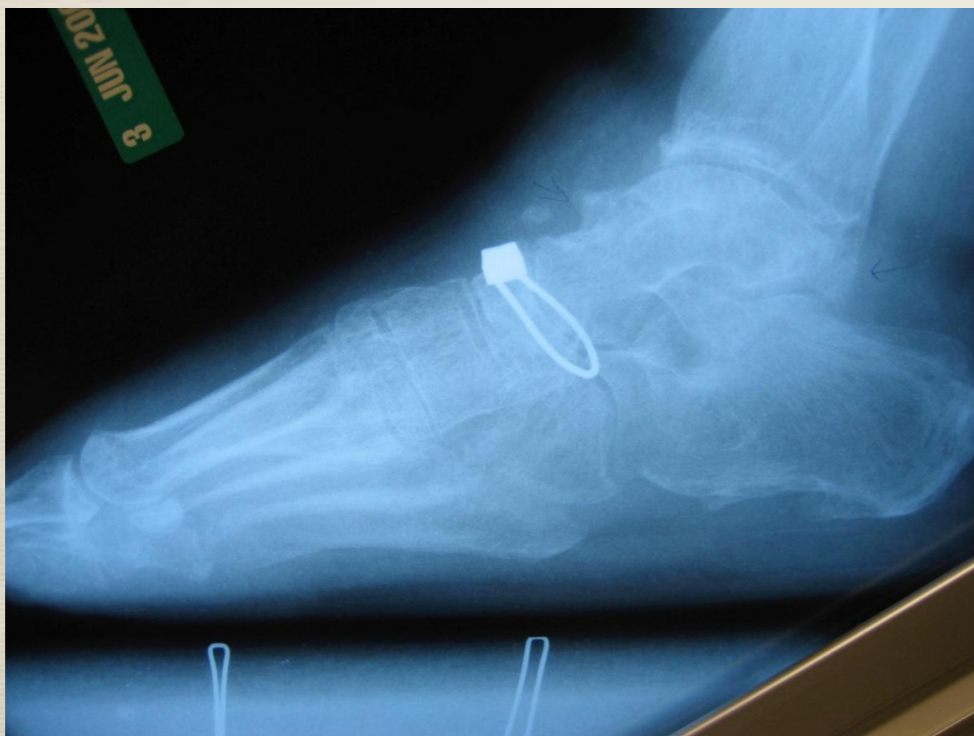
Additional Illustrative Post-operative Case Images



Pre-Operative Images



Post-Operative Images



References

- 1. Naidu V, Singh S, et al. Cerclage Wire Fixation of Navicular Body Fractures – A Treatment Based on Mechanism of Injury. Foot & Ankle International. 26 (3): 267-269. 2005**

- 2. Kupcha P, Freeland E et al. Fixation of Navicular Body Fractures With a Cerclage Wire Technique. Techniques in Foot & Ankle Surgery. 14(4):177-180, December 2015**